

## Histopathological Spectrum of Urothelial Lesions

Bhavana Grandhi M.D.,<sup>1</sup> Syama Sundara Rao Byna M.D.,<sup>2</sup>  
Vissa Shanthi M.D.,<sup>3</sup> B.V.Vydehi M.D.,<sup>4</sup> N.Mohan Rao M.D.,<sup>5</sup>  
Ankita Goel M.D.<sup>6</sup>

<sup>1</sup>Assistant Professor, Dept. of Pathology, Narayana Medical College, Nellore Andhra Pradesh, India.

<sup>2</sup>Associate Professor, Dept. of Pathology, Narayana Medical College, Nellore Andhra Pradesh, India.

<sup>3</sup>Professor & HOD, Dept. of Pathology, Narayana Medical College, Nellore Andhra Pradesh, India.

<sup>4</sup>Professor Dept. of Pathology, Narayana Medical College, Nellore Andhra Pradesh, India.

<sup>5</sup>Associate Professor, Dept. of Pathology, Narayana Medical College, Nellore Andhra Pradesh, India.

<sup>6</sup>Assistant Professor, Dept. of Pathology, Narayana Medical College, Nellore Andhra Pradesh, India.

---

### Abstract:

#### Introduction

Tumors of the bladder are one of the most common urological lesions encountered in clinical practice. Cancer of the urinary bladder is the 7<sup>th</sup> most common cancer worldwide which constitutes for 90% of all primary tumors of the bladder. The present study was undertaken to review the histopathological lesions of the bladder, determine the age, sex, incidence of these tumours along with grading and staging.

**Objectives:** 1. To identify the various histopathological lesions of the urinary bladder 2. To determine the demographic characteristics of the bladder lesions.

**Methods:** A one year prospective study of the urothelial lesions was carried out in the Department of Pathology, Narayana Medical College, Nellore. Related clinical history of all these cases were recorded.

**Results:** The present study was conducted over a period of one year during which a total of 48 lesions were evaluated. Malignant lesions were more common with a male predominance. The peak age of incidence of the lesions was 61-70 years. Hematuria was the most common presenting complaint. High grade invasive urothelial carcinoma was the most common histopathological lesion encountered in our study.

**Conclusion:** Bladder cancer has become very common nowadays. These tumors when presented in the advanced stage have an overall poor survival rate. Pathological grading plays a key role in the prognosis of these tumors.

**Keywords:** Bladder cancer, Hematuria, Urothelial lesions.

---

### I. Introduction

Bladder cancer is one of the commonest tumors world wide. In the United States, it is the 7<sup>th</sup> most common cancer and in Asian countries it is the 6<sup>th</sup> most common cancer.<sup>1</sup> Thus the prevalence is higher in developed than in the developing countries.<sup>2</sup> They are an important cause of morbidity and mortality.<sup>3</sup> with the most common clinical sign being gross and microscopic haematuria in majority of the patients.<sup>4</sup> Male predominance is common worldwide<sup>5</sup> with the risk factors being environmental factors, industrial exposure to arylamines, long term use of analgesics, cigarette smoking and infestation with *Schistosoma hematobium*.<sup>6</sup> Bladder cytology plays a key role in the diagnosis of bladder tumors.<sup>7</sup>

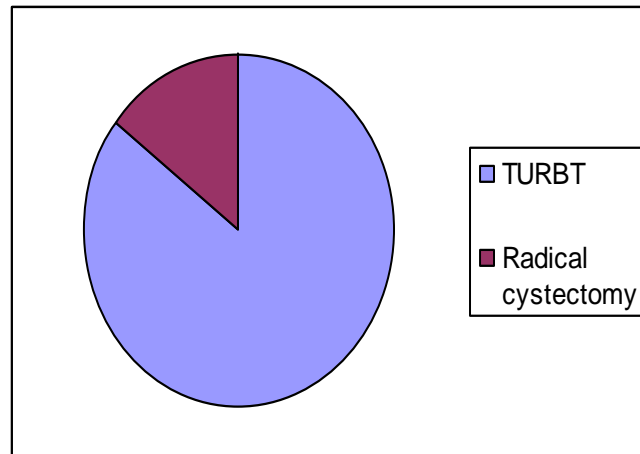
### II. Methodology

A prospective study was done over a period of one year in the Department of Pathology, Narayana Medical College, Nellore. We received a number of cystoscopic biopsies as well as resected specimens. Routine processing was done starting from fixation, dehydration, embedding and section cutting. Staining was done by H&E in most of the cases with the help of special stains wherever necessary. The slides were examined and diagnosed with the help of WHO/ISUP classification(2004) and TNM staging for grading and staging of the tumors respectively. Data was analysed and tabulated for evaluation.

### III. Results

A total number of 48 cases were studied. Relevant clinical history was taken and appropriate investigations wherever necessary were recorded. The morphological features were studied and analysed in detail. Out of the total cases, only 7 cases (14.58%) were radical cystectomy specimens and the remaining 41 cases (85.42%) were TURBP specimens. Figure 1

Figure1: Specimen categorization



Age of the patients in our study ranged from 7 years to 85 years with a peak age incidence of cases in the 6<sup>th</sup> decade, 17 cases (35.42%) followed by the 5<sup>th</sup> decade, 11 cases (22.9%). Least number of cases were seen in the 2<sup>nd</sup> to 3<sup>rd</sup> decade. Table 1.

**Table1:** Age distribution of urothelial lesions

Age distribution	Number of cases
0-10	2
11-20	1
21-30	1
31-40	4
41-50	5
51-60	11
61-70	17
71-80	4
81-90	3
Total no.of cases	48

Males were more commonly affected than females with M:F ratio of 4.3:1. The commonest symptom symptoms with which most of the patients presented were haematuria, 36 cases (75%) followed by abdominal pain 7 cases (14.58%) and the remaining 5 cases (10.41%) presented with urgency.

**Table 2:** Chief complaints

Chief complaints	Number of cases(%)
Hematuria	36(75%)
Abdominal pain	7(14.58%)
Urgency	5(10.41%)

In the benign conditions, a variety of lesions were encountered ranging from cystitis to granulomatous lesions. Table 3.

**Table3:** Benign lesions

Benign condition	Number of cases(%)
Eosinophilic cystitis	1(6.25%)
Hemorrhagic cystitis	1(6.25%)
Non specific cystitis	7(43.75%)
Granulomatous, fungal	5(31.25%)
Granulomatous, koch's	1(6.25%)
Mesonephroid metaplasia	1(6.25%)

In the malignant category, the most common histopathological variety was high grade invasive transitional cell carcinoma accounting for a total of 11 cases (34.375%), 6 cases (18.75%) were high grade non-invasive transitional cell carcinoma, 7 cases (21.875%) each of low grade transitional cell carcinoma, invasive

and non-invasive respectively. 1 case was diagnosed as PUNLMP and 1 case was diagnosed as high grade transitional cell carcinoma with squamous differentiation. Table 4: Malignant lesions

**Table 4: Malignant lesions**

Malignant lesion	Number of cases
High grade invasive	10(31.25%)
High grade non-invasive	6(18.75%)
Low grade invasive	7(21.875%)
Low grade non-invasive	7(21.875%)
PUNLMP	1(3.125%)
Invasive with squamous differentiation	1(3.125%)

#### IV. Discussion

A number of benign lesions were seen in our study. Eosinophilic cystitis is an inflammatory condition of the bladder which can be idiopathic or can be associated with triggers like food allergens, asthma or allergic gastroenteritis. On cystoscopy the appearance is variable with ulcers, exudates, edematous bullae or polyps. Microscopically, edematous lamina propria is seen with a mixed inflammatory infiltrate, predominantly eosinophils. Granulomatous cystitis is seen as an erythematous or polypoidal inflammation on cystoscopy. Microscopy shows caseating or non caseating granulomatous inflammation with epithelioid histiocytes and multinucleated giant cells in the lamina propria of the bladder.<sup>8</sup>

Urothelial tumours account for 90% of all cancers of the bladder and vary from small benign lesions that may never recur to aggressive cancers associated with high mortality. Molecular genetics suggest a number of alterations in urothelial carcinoma. The most common alterations are seen in chromosome 9 which may be monosomy or deletion of 9p or 9q. These genetic changes are most commonly seen in non invasive tumors. On the other hand, many invasive urothelial cancers show deletions of 17p which include the region of p53. Thus, alterations in p53 contribute to the progression of urothelial carcinoma.<sup>3</sup>

The two distinct precursor lesions are non invasive papillary tumours and flat non invasive urothelial carcinoma, the former being the most common.<sup>3</sup> Transitional cell carcinoma also termed as urothelial carcinoma of bladder is a major cause of morbidity and mortality throughout the world, typically seen in patients above the age of 50 years.<sup>9</sup> It is conventionally of two types, papillary and non papillary (flat-sessile). Non invasive papillary carcinoma account for about 25% of primary transitional cell carcinoma of the bladder. The other variants are:

- (i) glandular or squamous differentiation
- (ii) nested carcinoma
- (iii) microcystic carcinoma
- (iv) micropapillary
- (v) sarcomatoid
- (vi) trophoblastic differentiation
- (vii) unusual stromal changes

PUNLMP, papillary urothelial neoplasm of low malignant potential is an entity which deserves a little discussion at this juncture. It is defined as papillary urothelial tumor with abnormally thick urothelium, but lacking cytologic atypia. These category of tumours share few features of similarity with papilloma. Grossly at the time of cystoscopy these lesions are a little larger than papillomas, typically measuring less than 2 cm. Microscopically these lesions have either thicker urothelium or diffuse nuclear enlargement than papillomas. Robbins Papillae are seen lined by thickened urothelium (more than seven cell layers) with a monotonous population of cells, often in a parallel pattern.<sup>8</sup>

Low grade papillary urothelial carcinoma are characterized by an orderly appearance both architecturally and cytologically.<sup>3</sup> It is defined as a papillary neoplasm lined by urothelium with easily recognizable variation in cytologic features and characterized by an overall orderly appearance of the urothelium lining papillary fronds. The cells are evenly placed and cohesive. There is minimal nuclear atypia consisting of scattered hyperchromatic nuclei, infrequent mitotic figures and mild variation in size and shape. Though infrequent, low grade cancers can recur with evidence of invasion.<sup>8</sup>

High grade papillary urothelial carcinoma is defined as a urothelial neoplasm exhibiting papillary fronds which shows a significantly disordered architectural and cytologic pattern with moderate cytologic atypia.<sup>8</sup> It contains cells that are dyscohesive with large hyperchromatic nuclei, high degrees of anaplasia and atypical mitotic figures. Architectural disarray with loss of polarity is a characteristic feature of these tumors. Urothelium is likely to be denuded with prominent cellular detachment. Variable amount of squamous differentiation and glandular differentiation may be seen. The former is characterized by keratinization and presence of intercellular bridges.<sup>8</sup>

Higher incidence of muscular invasion is seen in the high grade tumours(80%) when compared to the low grade tumours(10%)<sup>3</sup>. Invasion is seen as single cells or urothelial nests<sup>8</sup>. Aggressive tumors extend into the bladder wall, adjacent prostate, seminal vesicles, ureters and retroperitoneum. Fistulous communications to the vagina or rectum are produced in some tumors.<sup>3</sup>

In our study, malignant tumours,32cases(66.67%) predominated over benign lesions,16cases(33.33%).Similar findings were observed in the study done by Vaidya et al.<sup>10</sup> Among the malignant tumors, majority of the lesions were high grade,17cases(53.12%) compared to low grade,14 cases(43.75%) in our study correlating with the studies done by Vaidya et al<sup>10</sup> and Mahesh et al.<sup>2</sup> wherein high grade transitional cell carcinoma accounted for 43.21% and 53.57% respectively. In contrary to our studies, low grade was more common than high grade transitional cell carcinoma in the studies done by Laishram et al<sup>11</sup> and Ahmed et al<sup>12</sup> accounting for 53.85% and 44% respectively.

Tumor staging and grading are currently the two major factors for recurrence, progression and for determination of treatment options for patients with bladder cancer.<sup>13</sup>In our study, muscle invasion was seen in 17 cases() out of 32 cases, among which 10 cases were high grade and the remaining 7cases were low grade. In the study done by Vaidya et al<sup>10</sup> 24 cases (35.92%) showed muscle invasion out of total 67 cases, out of which 20cases were high grade and 4 cases were low grade. Similar findings were also observed in the study done by Laishram et al.<sup>11</sup> A rough estimate of 40% of the tumors, especially deeply invasive tumors metastatize to the regional lymph nodes. Hematogenous dissemination, principally to the liver, lungs and bone marrow has been recorded in the literature.<sup>3</sup>

## V. Conclusion

In our study, bladder tumors were the most common lesion among which transitional cell carcinoma was the predominant prototype.Majority of them were high grade with muscle invasion.Grading of the muscle and invasion of the muscle are the most valuable predictors of survival. It is thus important to include smooth muscle in the biopsy specimens of the bladder lesions especially when suspecting malignancy.

## References

- [1]. RGI and Census Commissioner(2006) Census of India.New Delhi: Office of registrar general and census commissioner, Ministry of Home Affairs, Government of India.
- [2]. Mahesh KU, Yelikar BR, Spectrum of lesions in cystoscopic bladder biopsies- A histopathological study. *Al Ameen J Med Sci.*2012;5(2):132-6.
- [3]. Epstein JI. The lower urinary tract and male genital system. In: Kumar V, Abbas AK, Fausto N,eds. *Robbins and Cotran Pathologic Basis of Disease.*7<sup>th</sup> ed. Philadelphia: Saunders; 2004.p 1023-58
- [4]. Murphy DM, Zincke H, Furlow WL. Management of high grade transitional cell cancer of upper urinary tract. *J Urol.*1981;125:25-9.
- [5]. Ferlay J, Soerjomataram I, Ervik M,Dikshit R, Eser S, Mathers C, Rebelo M, Parkin DM, Forman D, Bray, F. *GLOBOCAN 2012.*
- [6]. Howlader N, Noone AM, Krapcho M, Garshell J, Neyman N, Altekruse SF, Kosary CL, Yu M, Ruhl J, Tatalovich Z, Cho H, Mariotto A, Lewis DR, Chen HS, Feuer EJ, Cronin KA(eds). *SEER Cancer Statistics Review, 1975-2011*, National Cancer Institute.
- [7]. [Shanthi V, Shyam Sundara Rao B, Mohan Rao N, Bhavana G, Reddy VC, Swathi S. Diagnostic efficacy of Urine cytology for screening of Bladder Cancer: A retrospective study. International Journal of Medical Research and Review 2016;3\(2\):23-26.](#)
- [8]. Ming Zhou,George J.Netto,JonathanI.Epstein Urothelial lesion.In:*Urothelium:High Yield Pathology*;Saunders2012.p133-231.
- [9]. JohnN.Elbe,RobertH.Young Tumours of the urinary tract. In:ChristopherD.M.Fletcher. *Diagnostic Histopathology of tumours.*3<sup>rd</sup> ed.Elsevier 2007.p523-536
- [10]. Vaidya et al. Urothelial tumors of the urinary bladder : A histopathological study of cystoscopic biopsies,*JNMA* 2013;52(7):475-478.
- [11]. Laisram RS, Kipgen P, Laishram S,Khurajam S, Sharma DC.Urothelial tumors of the urinary bladder in Manipur: A histopathological perspective. *Asian Pac J Cancer Prev.*2012;13(6):2477-9
- [12]. Ahmed Z, Muzzafer S, Khan et al. Transitional cell carcinomas of urinary bladder. A histopathological study. *J Pak Med Assoc.*2002;52:396-8
- [13]. Matalaka I, Bani-Hani K, Shotar A, Bani-Hani O, Bani-Hani I.Transitional cell carcinoma of the urinary bladder: A clinicopathological study.*Singapore Med J* 2008;49(10):790-4.